

**DERMATOLOGY: NOT EVERYTHING IS AS SIMPLE AS IT SEEMS. DIFFICULTIES IN DIAGNOSIS.**

**Yusupaliev U.A.**  
**Mukhamedov B.I.**  
**Ibragimova N.S.**  
**Pyagai G.B.**  
**Solmetova M.N.**

*Tashkent Medical Academy<sup>1</sup>.*  
*Tashkent State Dental Institute<sup>2</sup>*

**Summary:** *The article describes the difficulties in diagnosing dermatosis and the specifics of counseling such patients by a dermatologist. We present our own clinical observation.*

**Keywords:** *dermatoses, diagnostic errors.*

Dermatology today is a rapidly developing branch of medicine, in connection with the disclosure of new etiopathogenetic aspects of skin diseases. All this became possible thanks to the achievements of modern science, the emergence of a large arsenal of diagnostic methods. Despite this, the diagnosis of human skin diseases remains a difficult problem. This is explained not only by the wide variety of dermatoses, their clinical forms, manifestations at different stages of the disease, but, sometimes, by the transformation of the disease, the change in clinical manifestations, depending on the use of external therapy, when even a biopsy shows nonspecific changes. All this creates a large field for diagnostic search, which often leads to the discovery of disparate data, which further confuses the doctor. This circumstance contributes to the patient's going from one doctor to another and *therapiya ex juvantibus*.

We present our own observation.

Patient M, aged 33, turned to various dermatologists with complaints about the appearance of a formation in the region of the inguinal fold on the right, slight pain.

Status localis: The skin pathological process is limited, subacute inflammatory in nature and is located on the skin of the right inguinal fold, in the form of a linear cord, 7 cm long. In the focus, there is infiltration, lichenification and small-lamellar peeling. Phenomena of weeping, pyoderma are absent.

Subjectively: no complaints

He underwent the following laboratory and instrumental studies:

UAC - without features.

IgE 100 IU/ml,

scraping from the lesion: found *St. aureus*; mushrooms were not found.

The concentration of C-reactive protein 12.8 (normal up to 8.0)

Cholesterol 5.46 mmol / l (norm up to 5.20)

Total protein 91 g/l (norm up to 87)

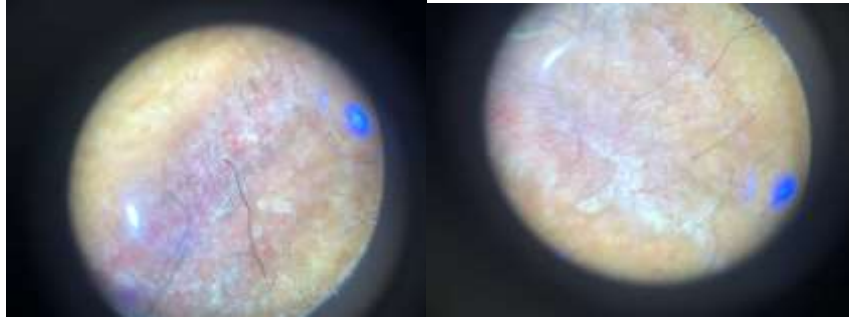
Lambia intestinalis 0.176 (control 0.251)

Ascaris lubricoides 0.373 (control 0.312)

Candida albicans 2.999 (control 0.291)

Helicobacter pylori 0.045 (control 0.299)

Dermatoscopy



Histological examination: (referral diagnoses: neurodermatitis, fistula, pyoderma, eczema) slight hyperkeratosis, detachment of the stratum corneum in places, uneven acanthosis alternating with areas of flattened epidermis, the basal layer is overloaded with pigment. In the dermis, lymphatic vessels of the capillary structure with the content of lymphoid fluid are determined in large numbers, proliferation of endotheliocytes is noted, lymphocytic infiltration is determined around the vessels, collagen fibers are basophilically changed, skin appendages are preserved.

Conclusion: the morphological picture is more consistent with a limangioma.

Within 6 months the patient received a variety of treatments, including aniline dyes, corticosteroids externally. Another examination by another dermatologist showed that the clinical picture did not correspond to lymphangioma, the patient received antifungal treatment.

A second biopsy was recommended, which ruled out lymphangioma and showed non-specific changes more characteristic of "exhausted skin".

At the last examination, a slight irritation was noted at the site of the focus, which was practically epithelialized (photo).

It was recommended: emollients 2 times a day for 1 month, after which the skin pathological process completely regressed.

This case demonstrates how difficult it is to make a diagnosis. It is very important that the basis of correct diagnosis is a comprehensive methodical approach, with the repeated use of histological examination and their collegial consideration, in order to clarify the diagnosis. In his guide, T.R. Harrison said, "Identification of skin lesions, or changes, is a problem similar to that of recognizing cells in a blood smear: the smallest details make a huge difference." Therefore, it is fair to say that the diagnosis of skin

diseases is one of the most difficult sections of clinical diagnostics and to a greater extent depends on the doctor's approach. (1).

**LIST OF USED LITERATURE:**

1. Gorbuntsov V.V., Dyudyun A.D. // Dermatovenereology. Cosmetology. Sexopathology.-№1-4.- 2014.-p. 139
2. G.B. Pyagay, K.A. Yuldashev Comparative analysis of the therapeutic efficacy of various methods of treatment of syphilis patients suffering from drug addiction News of dermatovenereology and reproductive health. 2005, No. 3-4, pp. 118-122.
3. Boris Lyuban, Bahrambek Mukhamedov, Nargiza Ibragimova, Grigory Pyagai, Miyassar Allaeva, Nilufar Malikova, Malika Solmetova cases of medical errors in the primary period of syphilis <http://medin.uz/index.php/jmi/article/view/71>  
<http://medin.uz/index.php/jmi/article/view/71/62>
4. Lapasov, O. A., & Latipov, I. I. (2022). basal cell skin cancer. historical aspects, current achievements and problems at the present stage. central asian journal of medical and natural science, 3(5), 381-391. retrieved from <https://cajmns.centralasianstudies.org/index.php/CAJMNS/article/view/1109>
5. Lapasov, O. A., Zaslavsky, D. V., Sidikov, A. A., Pyagay, G. B., Kozlova, D. V., & Gunchenko, I. V. (2022). Basal cell skin cancer. Historical aspects, current achievements and problems at the present stage. Dermatovenereology. Cosmetology, 8(1), 27-42.. <https://www.elibrary.ru/item.asp?id=48197950>
6. A.A Sidikov, A.T Makhmudov, G.B Pyagay, J.R Rikhsiboev Importance of questionnaires in the diagnosis of diseases of the urogenital tract-development of new technologies in the diagnosis and 2021 <https://www.elibrary.ru/item.asp?id=45597101>
7. T Lotti, AA Sydikov, Z Zarrab, GB Pyagay... Aesthetic concerns in oncological dermatology: a case of successful treatment with imiquimod and interferon- $\alpha$  for primary anaplastic large-cell cd30+ t-lymphoma of the skin - Journal of Applied Cosmetology, 2019 <https://www.elibrary.ru/item.asp?id=44794514>
8. M.N Solmetova, M.D Allaeva, B.I Mukhamedov Clinical case of pseudoxanthoma elastica - Dermatovenereology. Cosmetology, 2021 <https://www.elibrary.ru/item.asp?id=45428711>
9. D.V Zaslavsky, A.A Sidikov, L.V Garyutkina A new principle for diagnosing limited scleroderma at the onset of the disease - Russian journal of skin and venereal diseases, 2021 [https://scholar.archive.org/work/fkgqphdcizfyjfnqgv7x4bqaca/access/wayback/https://rj.svd.com/1560-9588/article/download/72328/pdf\\_1](https://scholar.archive.org/work/fkgqphdcizfyjfnqgv7x4bqaca/access/wayback/https://rj.svd.com/1560-9588/article/download/72328/pdf_1)
10. Пягай, Г., Ибрагимова, Н., Мухамедов, Б., Маликова, Н., & Аллаева М. (2021). клинический случай поздней диагностики пигментной крапивницы. медицина

- и инновации, 1(1), 148–150. извлечено от [https://inlibrary.uz/index.php/medicine\\_and\\_innovations/article/view/55](https://inlibrary.uz/index.php/medicine_and_innovations/article/view/55)
11. Zaslavsky D.V., Sidikov A.A., Garyutkina L.V., Pyagai G.B., Alaeva M.D., Ibragimova N.S., Malikova N.N., Kozlova D.V. A new principle for the diagnosis morphea in the onset of the disease // Russian Journal of Skin and Venereal Diseases. - 2021. - Vol. 24. - N. 3. - P. 263-274 <https://doi.org/10.17816/dv72328>  
<https://rjsvd.com/1560-9588/article/view/72328>
  12. А.А Садыков, Н.С Ибрагимова, А.А Юлдашев Зуд при коморбидных состояниях - ВА ЭСТЕТИК ТИББИЙОТ, 2015 [https://dermatology.uz/pdf/medic\\_jurantal/Dermatologiya\\_N1\\_2015.pdf#page=29](https://dermatology.uz/pdf/medic_jurantal/Dermatologiya_N1_2015.pdf#page=29)
  13. A Sidikov, D Zaslavsky, A Sadykov, N Ibragimova, M Megna, O Olisova, D Kozlova, R Nasyrov, E. Shalaeva, T Garcia The new differential diagnostic test for the lichenoid drug eruption Dermatologic therapy, 2020 <https://doi.org/10.1111/dth.13784>
  14. Ваисов А. Ш., Ташкенбаева У. А., Ибрагимова Н. С. Современные аспекты этиологии, патогенеза, течения и ранней диагностики васкулитов: обзор //Новости дерматовенерол. и репрод. здоровья. – 2007. – №. 2. – С. 88.
  15. И.У Салимова, Ш.Т Аюпова, Н.С Ибрагимова аспекты псориаза в дерматологии - Spirit Time, 2020 <https://www.elibrary.ru/item.asp?id=42780705>
  16. А.А Садилов, Н.С Ибрагимова, С.И Мавлянов - частота встречаемости кожной патологии у спортсменов при проведении углубленного медицинского осмотра (умо) и степень приверженности лечению. Безопасный спорт-2019. <https://www.elibrary.ru/item.asp?id=41357327>
  17. N Ibragimova, R Tregulova, N Normatova, S Djalalov-comparative analysis of the prevalence of type 2 diabetes according to the screening and register data in Uzbekistan - Endocrine Abstracts ISSN 1470-3947 (print) | ISSN 1479-6848 (online) <https://www.endocrine-abstracts.org/ea/0056/abstracts/poster-presentations-diabetes-obesity-and-metabolism/diabetes-to-include-epidemiology-pathophysiology/ea0056p342/>  
<https://doi.org/10.1530/endoabs.56.P342>
  18. Normatova N., Ibragimova N. Frequency of occurrence and factors of diabetic retinopathy advancement in people with DM type 2 in Uzbekistan //Endocrine Abstracts. – Bioscientifica, 2016. – Т. 41. <https://www.endocrine-abstracts.org/ea/0041/ea0041ep520> <https://doi.org/10.1530/endoabs.41.EP520>
  19. Ахмедова Ш.У., Абдуллаева О.И., Даминова М.Н., Алиева Г.Р., Ибрагимова Х.Н. функциональное состояние эритроцитов у детей и подростков с сахарным диабетом 1 типа на фоне микробиоценоза кишечника // нау. 2015. №4-4 (9). url: <https://cyberleninka.ru/article/n/funktsionalnoe-sostoyanie-eritrotsitov-u-detey-i-podrostkov-s-saharnym-diabetom-1-tipa-na-fone-mikrobiotsenoza-kishechnika>
  20. N.N Malikova, K.Y Karimov, K.T Boboev, S.S Arifov - The CYP17A1 rs743572 gene polymorphism and risk of development and clinical features of Acne

Vulgaris in the Uzbek population. International Journal of Biomedicine, 2019. <https://www.elibrary.ru/item.asp?id=38469333>

21. Arifov S.S., Erkinlar Z.E., & Malikova N.N. (2021). modern methods of acne and post-acne therapy. the American journal of medical sciences and pharmaceutical research, 3(09), 147–153. <https://doi.org/10.37547/TAJMSPR/Volume03Issue09-24>

22. Khudoykulova Farida Vafokulovna. (2022). NONALCOHOLIC FATTY LIVER DISEASE, MODERN CONSIDERATIONS. *Conference Zone*, 592–599. Retrieved from <http://www.conferencezone.org/index.php/cz/article/view/896>

23. Khudoykulova Farida Vafokulovna. (2022). NO ALCOHOL OF THE LIVER DIAGNOSTIC AND TREATMENT OF OBESITY DISEASE MODERN OBJECTIVES. *Conference Zone*, 600–605. Retrieved from <http://www.conferencezone.org/index.php/cz/article/view/897>

24. Akbarovna, K. S. (2022). uvb therapy for the treatment of patients with chronic dermatosis. central asian journal of medical and natural science, 3(5), 676-678. retrieved from <https://cajmns.centralasianstudies.org/index.php/CAJMNS/article/view/1152>

25. Н Юлдашова.распространенность факторов риска, влияющих на прогноз заболевания больных с артериальной гипертензией. <https://scholar.google.com/scholar?cluster=14053839193412833523&hl=en&oi=scholar>

26. Burxanova Gulnoza Lutfulloevna. (2022). OPTIMIZATION OF REHABILITATION FOR LESIONS OF THE LOCOMOTOR APPARATUS OF ATHLETES PARTICIPATED IN CHESS. *Conference Zone*, 404–409. Retrieved from <https://conferencezone.org/index.php/cz/article/view/876>

27. Ibragimova Malika Shavkatovna. (2022). characteristics of rehabilitation of children with cerebral palsy and speech defects. *conference zone*, 410–414. retrieved from <https://conferencezone.org/index.php/cz/article/view/877>

28. Mavlyanova Z. et al. Improving the tactics of treating children with severe cerebral palsy //European Journal of Molecular & Clinical Medicine. – 2020. – Т. 7. – №. 2. – С. 2020. [https://www.ejmcm.com/article/2366\\_b8ee379773f1c297c6f9892b076d2d7b.pdf](https://www.ejmcm.com/article/2366_b8ee379773f1c297c6f9892b076d2d7b.pdf)

29. Ibragimova Malika Shavkatovna. (2022). effectiveness of hydrokinesiotherapy in the rehabilitation of children with spastic cerebral palsy. *conference zone*, 507–511. retrieved from <http://conferencezone.org/index.php/cz/article/view/887>

30. Абдусаломова М. А., Мавлянова З. Ф., Махмудов С. М. оптимизация медико-социальной реабилитации при болезни дюшенна. [https://scientifictext.ru/images/PDF/2019/DNO-11-52/optimizatsiya\\_1.pdf](https://scientifictext.ru/images/PDF/2019/DNO-11-52/optimizatsiya_1.pdf)

31. Abdusalomova M.A., Mavlyanova Z.F., Khamrakulova F.M., Makhmudov S.M., Ravshanova M.Z. (2021). Children with Birth Trauma of the Cervical Spinal Cord and Spine (Obstetric Plexitis) According to the Age Periods. *Annals of the Romanian Society for Cell Biology*, 7077–7085. Retrieved from <https://www.annalsofrscb.ro/index.php/journal/article/view/877>
32. Maxmudov S., Mavlyanova Z., Jumanov J. Analysis bioindustries indicators of body composition of individuals at a young age, not engaged in physical culture //InterConf. – 2021.
33. Абдусаломова М А, Махмудов С М Достижения науки и образования. 2019. №11 (52). URL: <https://cyberleninka.ru/article/n/optimizatsiya-mediko-sotsialnoy-reabilitatsii-pri-bolezni-dyushenna>
34. Мавлянова З.Ф., Усманходжаева А.А., Равшанова М.З., Высогорцева О.Н., исмаилов ж.к. роль питания и питьевого режима в подготовке юных спортсменов, тренирующихся в условиях жаркого климата// Проблемы биологии и медицины. - 2021. №2. Том. 127. - С. 83-87. DOI: <http://doi.org/>
35. Мавлянова З.Ф., Уринов М.У., & Абдусаломова М.А. (2022). сузувчиларда нафас олиш тизимининг функционал ҳолатини ўрганиш. conference zone, 177–178. retrieved from <http://conferencezone.org/index.php/cz/article/view/551>
36. Мавлянова З.Ф., Уринов М.У., & Абдусаломова М.А. (2022). ЮРАК ҚОН ТОМИР ТИЗИМИНИНГ ФУНКЦИОНАЛ ХОЛАТИГА СУЗИШ СПОРТ ТУРИНИНГ ТАЪСИРИ. *Conference Zone*, 173–176. Retrieved from <http://conferencezone.org/index.php/cz/article/view/550>
37. Мухамедов, Б., Хаджиметов, А., & Садыков, А. (2022). взаимосвязь показателей липидного состава сыворотки крови и ацетилаторного статуса у больных вирусным гепатитом с проявлениями дерматологического характера. *research and education*, 1(9), 231–240. retrieved from <http://researchedu.org/index.php/re/article/view/976>
38. Лапасов С.Х., Хакимова Л.Р., Аблакулова М.Х., Валиева М.Х. диагностика, лечение и профилактика хронического гепатита б с позиции доказательной медицины // человек и его здоровье. 2015. №3. url: <https://cyberleninka.ru/article/n/diagnostika-lechenie-i-profilaktika-hronicheskogo-gepatita-b-s-pozitsii-dokazatelnoy-meditsiny>
39. Хакимова Л. и др. результаты оценки знаний и навыков слушателей последипломного медицинского образования посредством использования тестов множественного выбора //медицинское образование сегодня. – 2018. – с. 116. <http://elib.kirovgma.ru/sites/default/files/3-2-pb.pdf#page=116>
40. L.Khakimova, D. Abdukhamidova, M. Akhmedova, & M.Ablakulova. (2022). acne in allergic skin diseases. *texas journal of medical science*, 8, <https://zienjournals.com/index.php/tjms/article/view/1818>

41. Хусинова, Ш., & Аблакулова, М. (2017). Предиабет. Журнал проблемы биологии и медицины, (1 (93), 215–217. извлечено от [https://inlibrary.uz/index.php/problems\\_biology/article/view/2968](https://inlibrary.uz/index.php/problems_biology/article/view/2968)
42. Камалова, Ё., Наимова, Х., Мавлянова, З., & Набиев, З. (2014). физиотерапия при острых респираторных заболеваниях у детей и подростков. журнал проблемы биологии и медицины, (3 (79), 108. извлечено от [https://inlibrary.uz/index.php/problems\\_biology/article/view/5063](https://inlibrary.uz/index.php/problems_biology/article/view/5063)
43. Камалова Ё А, Джуманов Ж А Значение лечебной гимнастики в комплексе методов физической реабилитации больных остеохондрозом поясничного отдела позвоночника // вестник науки и образования. 2020. №23-3 (101). url: <https://cyberleninka.ru/article/n/znachenie-lechebnoy-gimnastiki-v-komplekse-metodov-fizicheskoy-reabilitatsii-bolnyh-osteohondrozom-poyasnichnogo-otdela>
- 44.